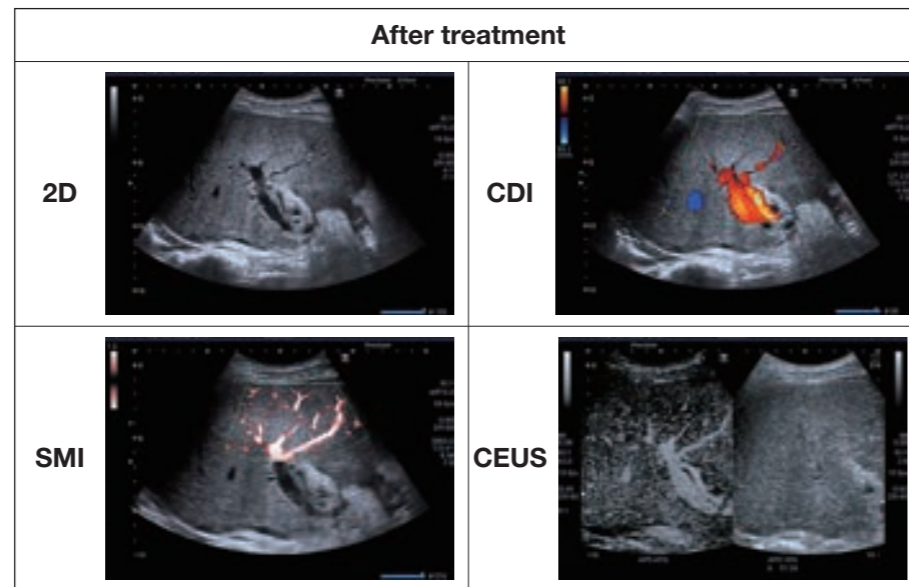


### 5. Future development for SMI on transplant evaluation

One of the potential uses for SMI is in the evaluation of transplanted organs. On current evaluation, this center has noted the powerful ability that SMI can provide in the assessment and success of liver transplant techniques.



### 6. Discussion

SMI is an innovative technology that provides outstanding vascular information in tiny, low-velocity flow states. SMI is applicable in different clinical regions and has a high sensitivity to detect vessels inside tumors and their blood supply. The detailed vascularity visualized by SMI allows the clinical professional to differentiate tumor malignancy and improves tumor

categorization.

SMI can provide detailed illustration of microvasculature without the use of contrast agents and the vasculature detection ability proved to be similar to CEUS. Arterial phase and vascular phase are shown simultaneously. It can serve as an effective tool for evaluating RFA treatment and support RFA planning and guiding.

Future improvement for SMI is needed as there is no quantification and may be affected by noise generated from heartbeat and breathing cycles. In addition, there is no perfusion so the arterial phase cannot be investigated in the same manner as CEUS.

### 7. Conclusion

SMI is a simple, intuitive tool that offers the ability to see the presently unseen and is able to replace the use of CEUS in some clinical areas. SMI has the ability to become a routine procedure for pre- and post-RFA treatment. There is a strong future

direction for SMI in detecting tiny vessels in abdominal and bowel areas and the evaluation of vessel reorganization in liver transplant that has potential to increase the quality of life.

In addition the ability to detect low-flow will benefit MSK and small

parts application. In regions where CEUS usage is limited or restricted, such as ocular, OBGYN, and pediatrics the routine use of SMI could also demonstrate considerable benefit.

## Roles of SMI in diagnosing liver disease and assisting in the planning of Radio-frequency ablation

Xie Xiaoyan

Professor, Director

Ultrasound Department, The First Affiliated Hospital of Sun Yat-sen University, Guangzhou, China

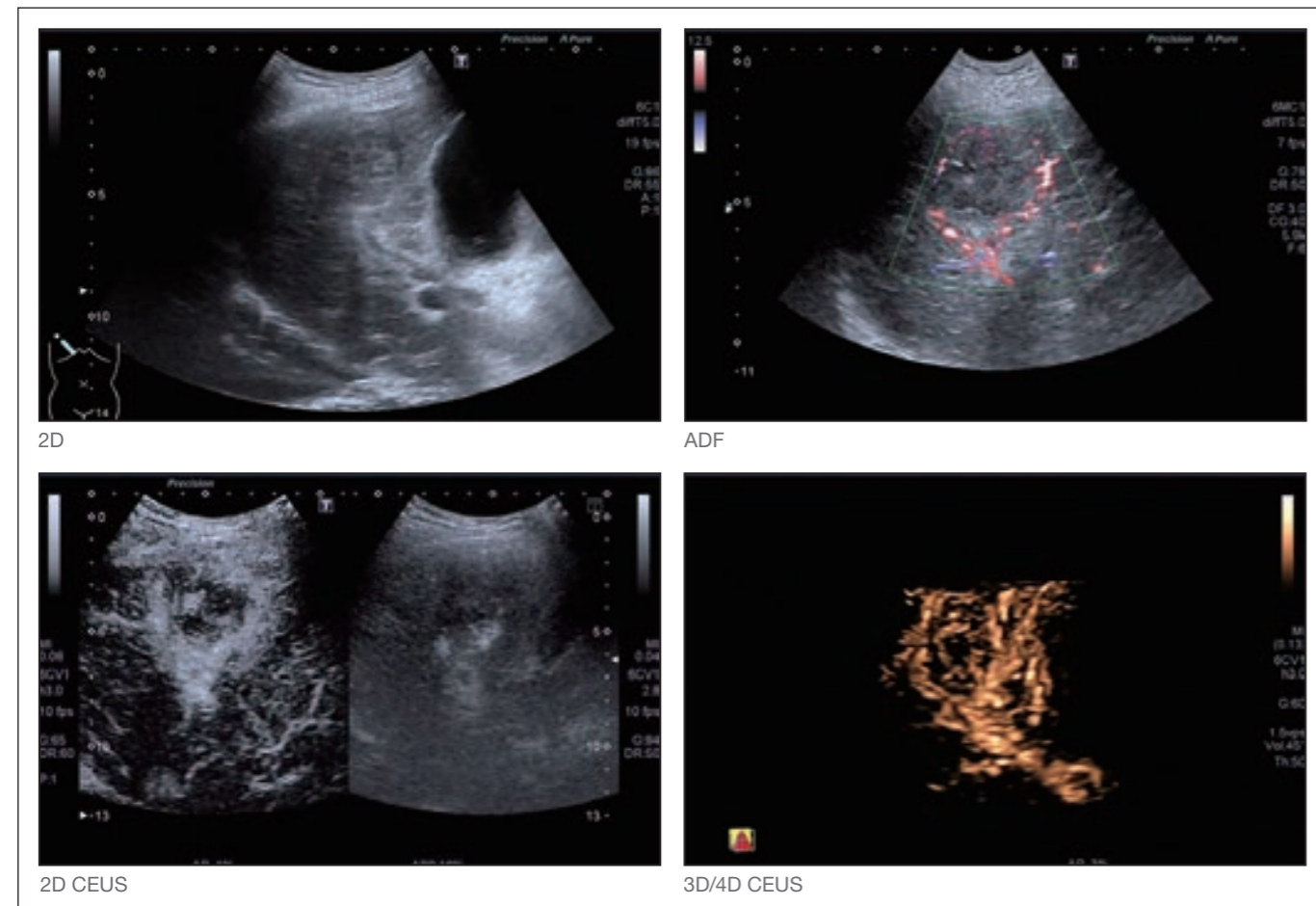


## Background

Diagnostic ultrasound is a non-invasive, radiation-free imaging modality that plays an important role in providing diagnosis, treatment planning and therapy evaluation in liver disease. Examination of vascular structures and flow dynamics is important in order to establish the malignancy of liver tumors and the planned therapy involving feeder vessel destruction. Conventional color Doppler has limitations in visualizing microvasculature and low velocity blood flows. Currently the gold standard in the diagnosis of liver disease is contrast-enhanced ultrasound (CEUS) which enables the increased sensitivity of vessel detection providing perfusion information. However, CEUS is not readily available

in all regions, impacting on the use of contrast agents. Moreover, the additional cost of the contrast agent may compromise treatment.

Radio-frequency ablation (RFA) is a minimally invasive treatment that is currently being used in the treatment of malignant liver disease. It is understood that RFA has a heat-sink effect that could destroy major vessels or nearby bile ducts, therefore treatment planning is particularly important for any RFA procedure. However the visibility of contrast agents during the ablative therapy will be of little use due to the release of nitrogen micro-bubbles during the therapy. CEUS is also a useful tool in post-treatment evaluation.

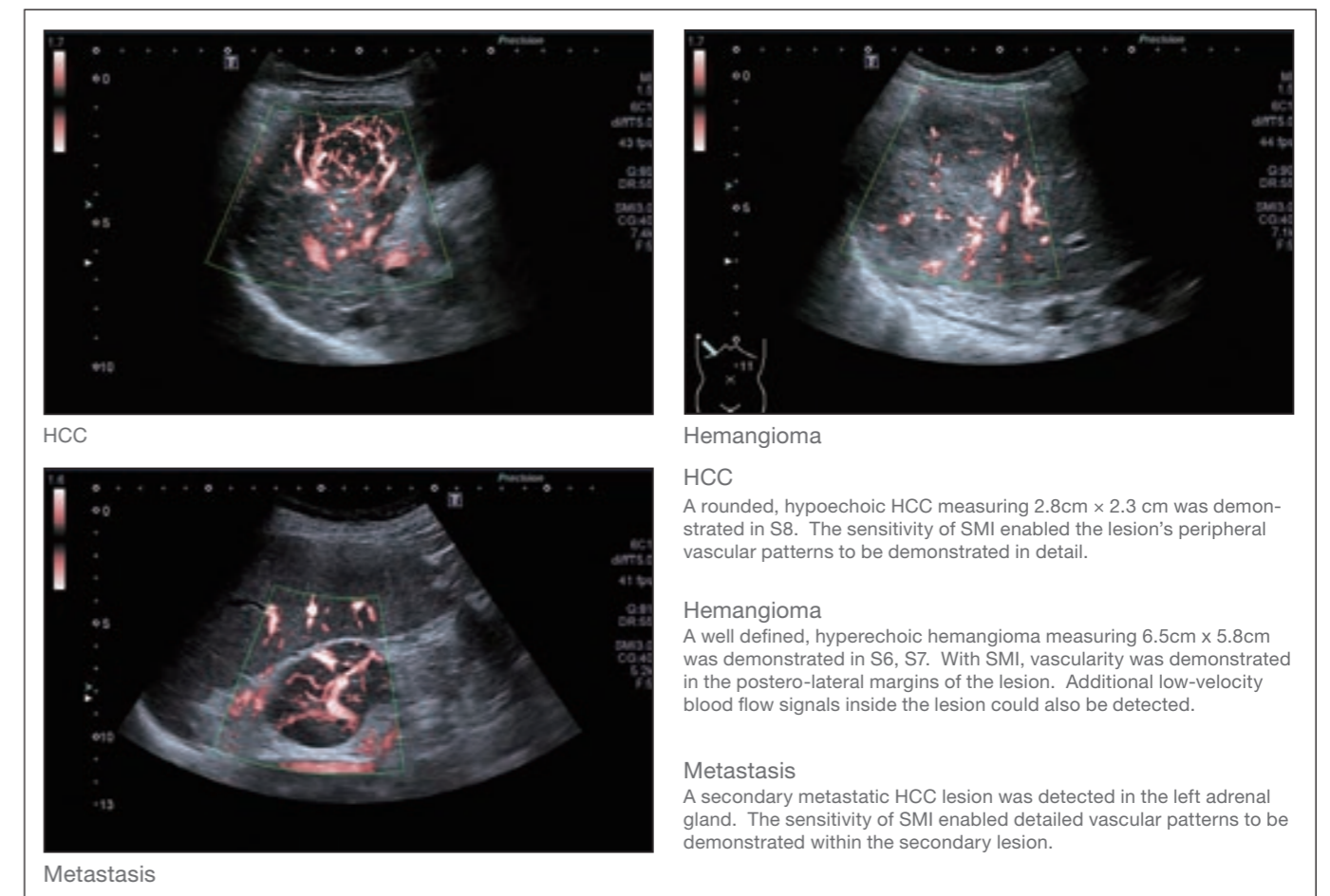
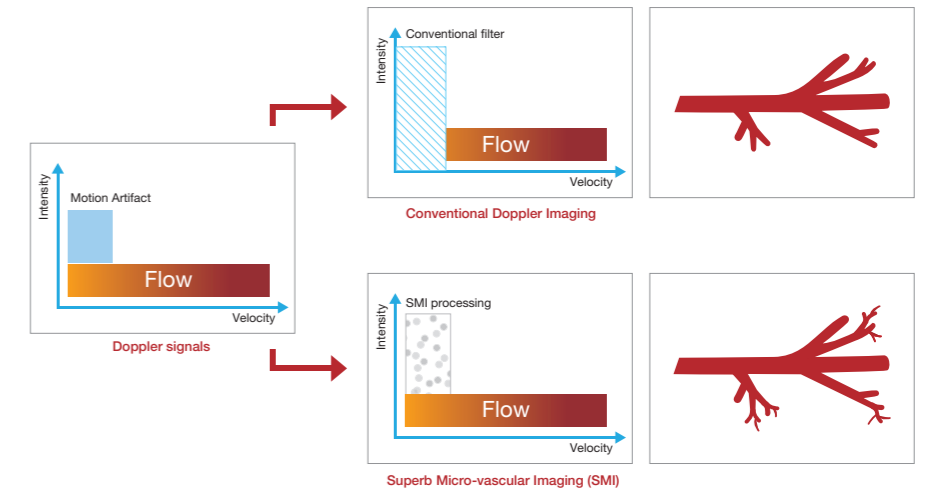


2D image of HCC with size 3.8 × 3.6cm. Feeder vessels are demonstrated with Advanced Dynamic Flow (ADF), Toshiba's unique technology for high resolution color flow imaging. The 2D CEUS enabled the true perfusion of the lesion to be demonstrated while the 4D CEUS allowed the lesion to be interrogated in 3 dimensions.

## 1. Introduce of SMI

Superb Micro-Vascular Imaging (SMI) is an innovative ultrasound Doppler technique developed by Toshiba. SMI offers a unique algorithm that allows visualization of microvasculature with low velocity but without using any contrast agents. The advantages of SMI include 1) low velocity flow visualization, 2) high resolution 3) minimal motion artefact, and 4) high frame rates.

- The exceptional vessel detection ability allows SMI to be of benefit in the evaluation and treatment of liver diseases. SMI has potential in:
- Display of minute intra-lesional vasculature
  - Evaluating RFA treatment
  - Support RFA planning and guiding



HCC

Hemangioma

HCC

A rounded, hypoechoic HCC measuring 2.8cm × 2.3 cm was demonstrated in S8. The sensitivity of SMI enabled the lesion's peripheral vascular patterns to be demonstrated in detail.

Hemangioma

A well defined, hyperechoic hemangioma measuring 6.5cm × 5.8cm was demonstrated in S6, S7. With SMI, vascularity was demonstrated in the postero-lateral margins of the lesion. Additional low-velocity blood flow signals inside the lesion could also be detected.

Metastasis

A secondary metastatic HCC lesion was detected in the left adrenal gland. The sensitivity of SMI enabled detailed vascular patterns to be demonstrated within the secondary lesion.

Metastasis

## 2. Display of minute intra-lesional vessels in liver

Blood vessels within lesions are typically small and difficult to detect with traditional Doppler. SMI provides

greater detail and visualization of tumor vasculature by detecting tiny, low-velocity vessels and therefore it

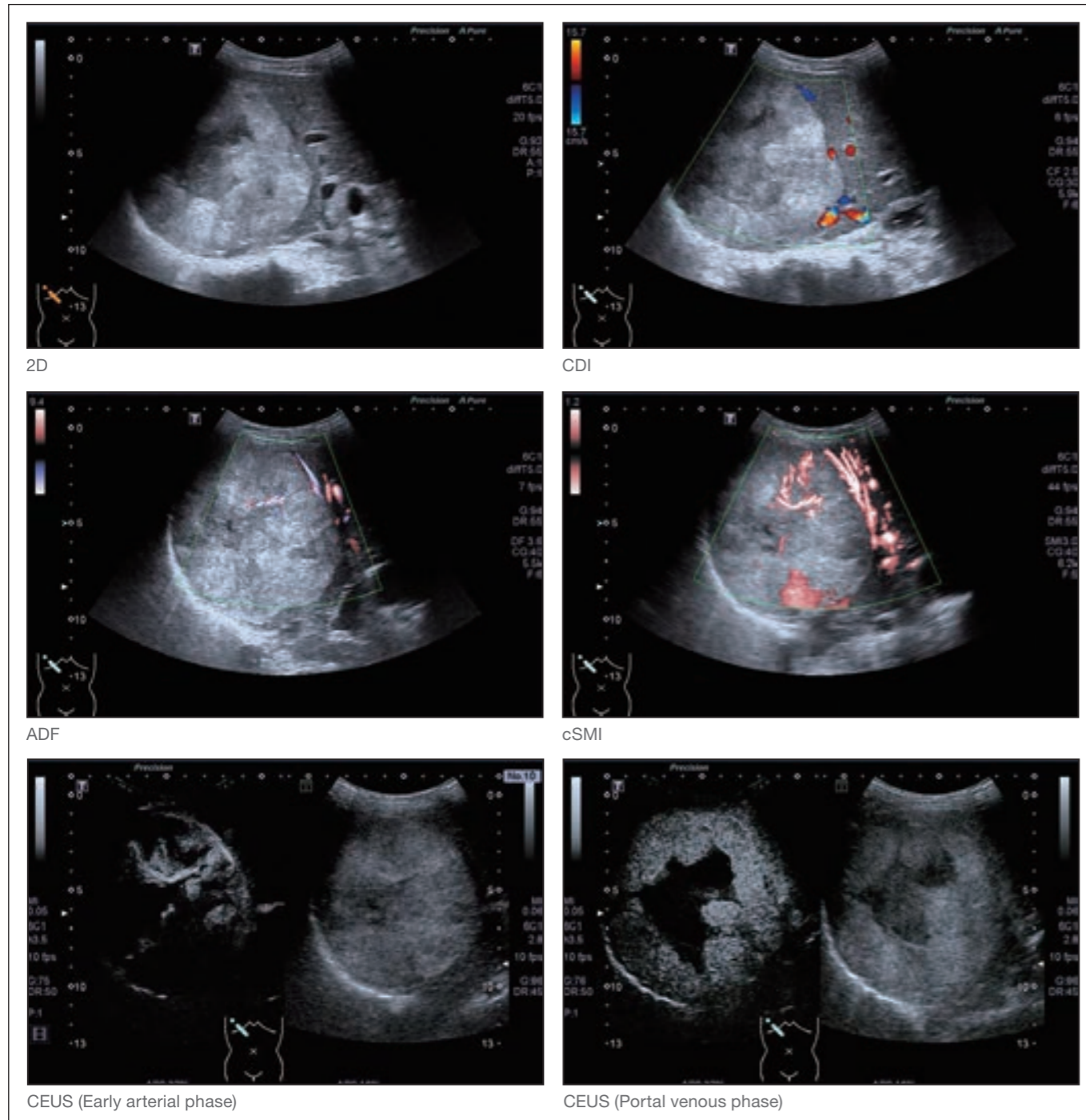
enables an increase in diagnostic confidence in the differentiation of malignancy.

### Case 1. HCC M 58Y

CDI could only detect a small amount of blood flow peripheral to the lesion. However, SMI was able to detect a detailed vascular pattern external to

the lesion at its antero-medial aspect as well as within the lesion. Feeder vessels were also demonstrated with SMI. CEUS showed centripetal

enhancement which emanated from the feeder vessels earlier detected with SMI. A hypo-enhancement pattern was seen in the late phase.

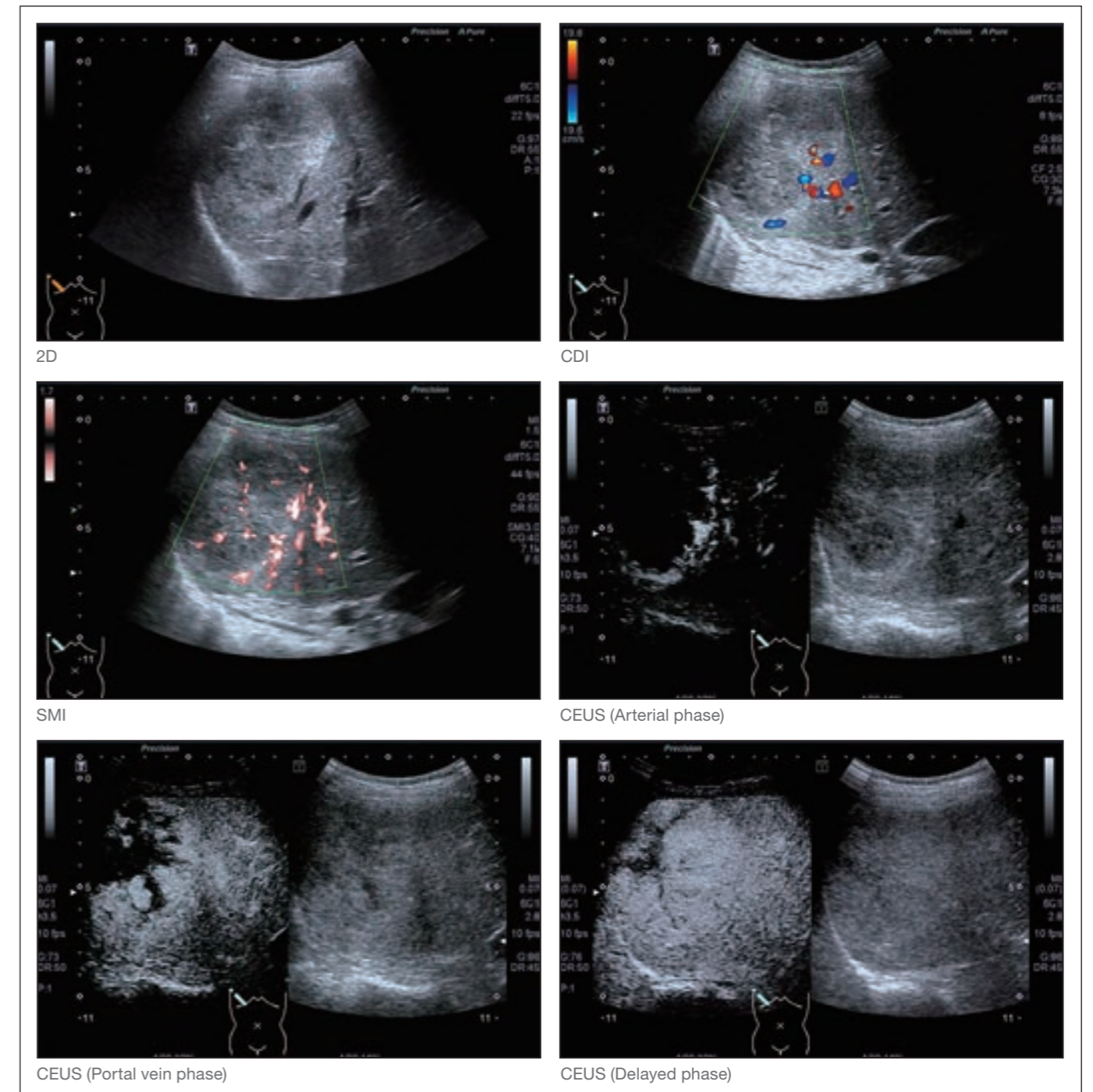


### Case 2. Hemangioma M 27Y

CDI could only detect a small amount of blood flow, peripheral to the lesion while in comparison, SMI demonstrated a detailed vascular pattern. In addition

to this, SMI also detected micro flow within the lesion. On CEUS, early enhancement was seen with the feeder vessels at the postero-lateral margins of the lesion, and demonstrating a

centripetal enhancement. There was homogeneous enhancement in the delay phase.

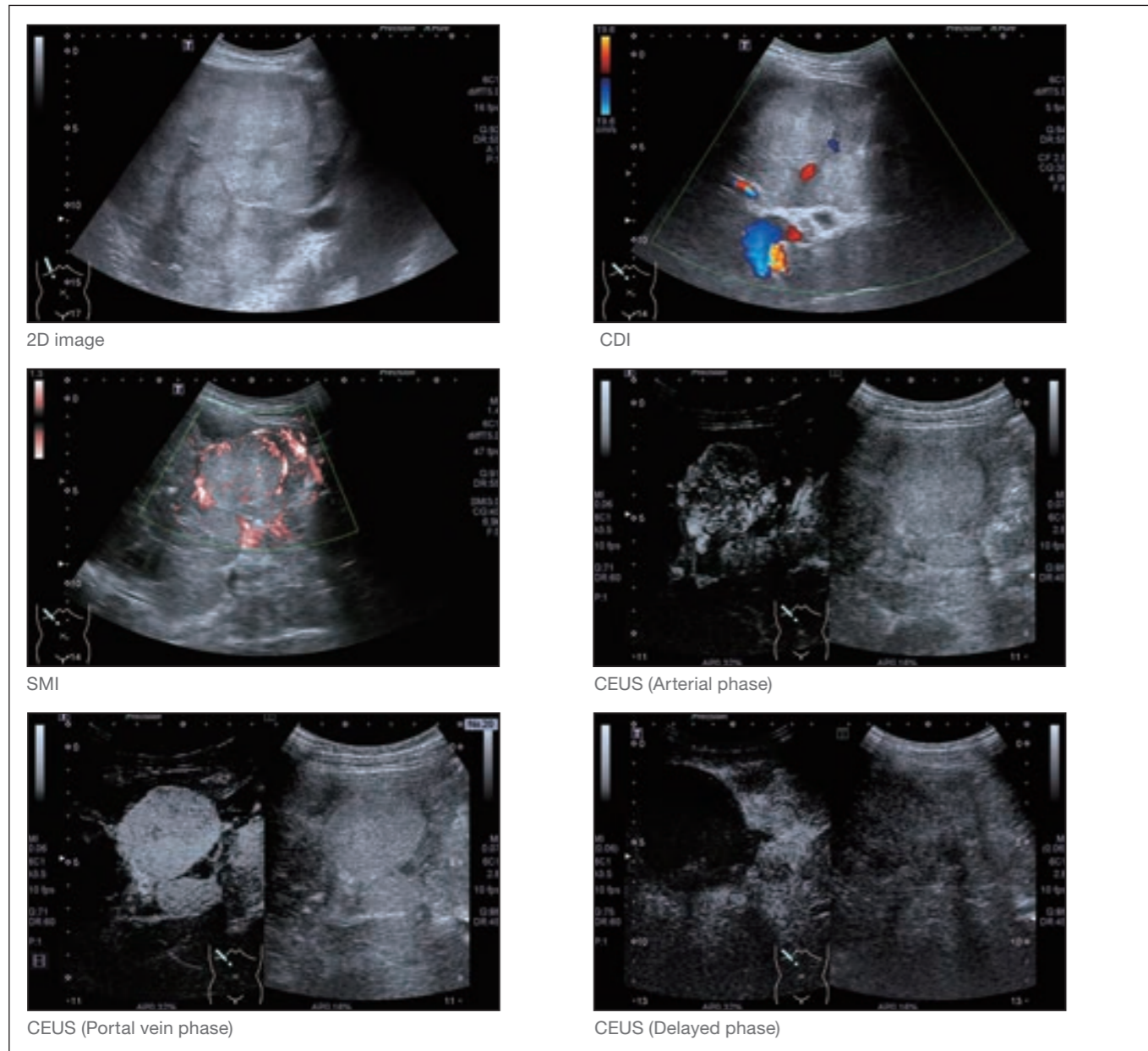


## Case 3. MLC (Liver metastasis by Neuroendocrine tumors) F 30Y

This patient presented with multiple liver lesions. Only small amounts of flow peripheral to the lesion could be demonstrated with CDI. However with SMI a basket-shape enhancement

was demonstrated peripheral to the lesion. In addition micro flow within the lesion was seen as a result of the increased sensitivity available with SMI. The flow pattern showed by SMI has

a high degree of similarity with CEUS vascular phase. In the late phase there is absence of enhancement. Histology confirmed malignancy.



SMI is able to visualize micro flows that have not previously been detected by conventional Doppler techniques. SMI increased sensitivity for blood flow detection, is a valuable tool in demonstrating internal vasculature especially for micro vessels.

A semi-quantitative analysis, Limberg classification (Table 1) on blood flow vascularization, was performed on 53 cases to compare conventional color Doppler versus SMI imaging technique. Vascularization of lesions is divided into 4 levels.

Table 1 . Limberg classification

Level 1	no flow
Level 2	Spot-like flow
Level 3	Bar-like flow
Level 4	Branch-like flow

Limberg classification	CDI	SMI
I		
II		
III		
IV		

CDI and SMI images for limberg classification.

We compared the blood flow detection ability between SMI and CDI (Table 2). Most patients showed vascularity at level 1 and 2 (68%) with CDI according to the Limberg classification, with 10 cases in level 1 showing no blood flow. 32.1% were classified as level 3 or 4 with CDI. Conversely, SMI

advanced sensitivity demonstrated an excellent vascularity detection ability, which 71.7% of patients were at level 3

or level 4. SMI is able to detect vascularity twice that of CDI.

Table 2 . Comparison of SMI vs CDI using Limberg classification (n=53)

	I	II	III	IV
CDI	10 (18.9%)	26 (49.1%)	10 (18.9%)	7 (13.2%)
SMI	10 (18.9%)	5 (9.4%)	14 (26.4%)	24 (45.3%)

## 3. Evaluation of RFA treatment

The cellular death during ablation caused formation of nitrogen micro-bubbles and causes difficulty for

contrast agent visualization and evaluation of needle position. SMI is not affected by the high signal created

by the micro-bubbles thus providing immediate evaluation of ablation results.

### Case 1. HCC F 73

Prior to RFA, CDI demonstrated blood flow within the prominent vessels peripheral to the lesion. With the greater sensitivity of SMI, a peripheral network of vessels surrounding the

lesion with the addition of micro flow within the lesion could be seen. The CEUS arterial phase demonstrated hyperenhancement.

After RFA, no vascularity could be

seen on either CDI or SMI. Follow up after 3 weeks post treatment, no vascularity could be demonstrated.

### Case 2. HCC M 43Y

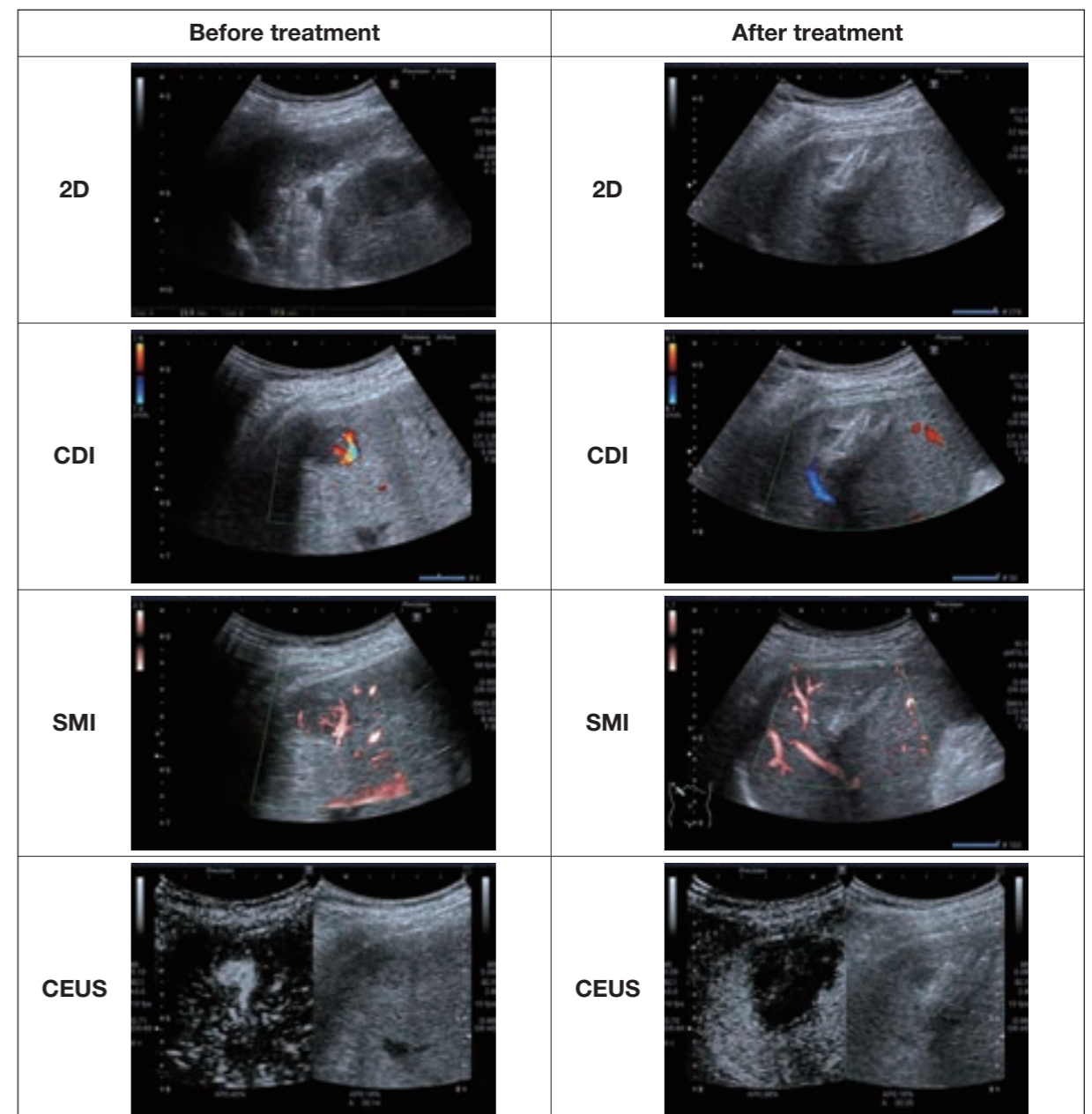
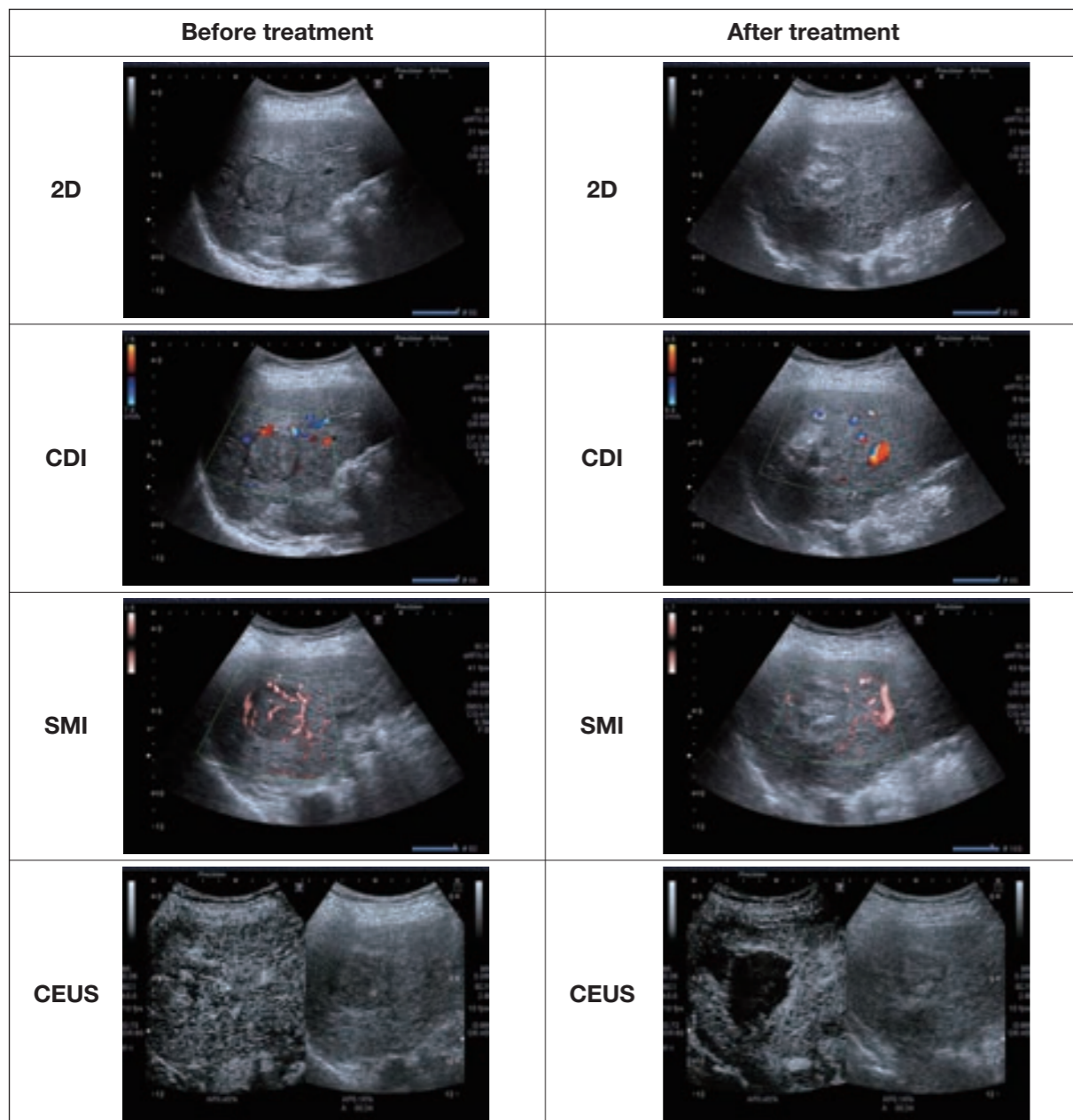
Before RFA, SMI detected blood flow both within the lesion and peripherally. CEUS demonstrated hyper-enhancement in arterial phase, and

hypo-enhancement in portal and delayed phase.

After treatment, no blood flow could be detected either within or peripheral

to the lesion.

Three week follow up post RFA with CEUS could not detect any lesion enhancement.



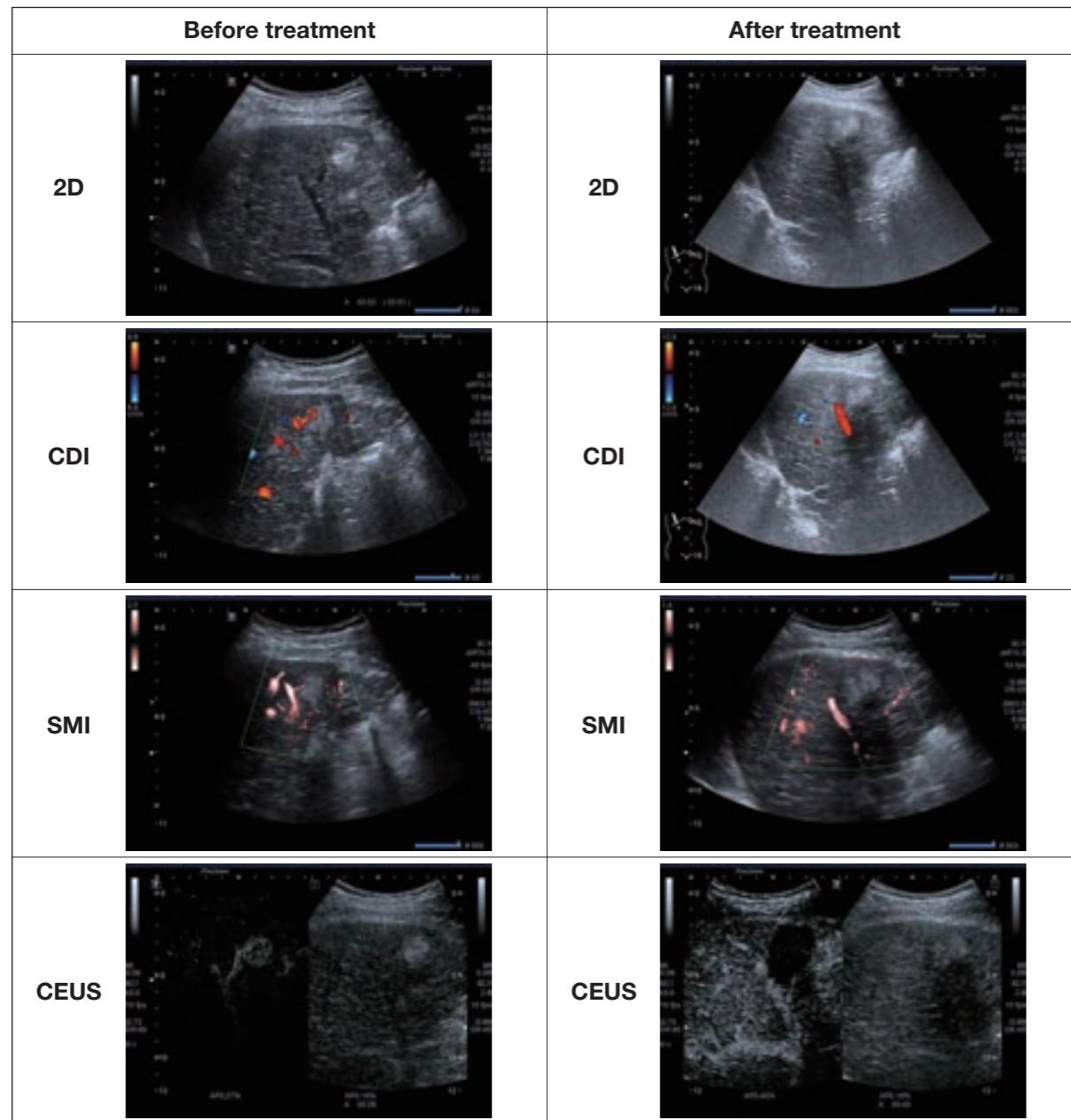
## Case 3. HCC M 58Y

Prior to RFA, CDI detected blood flow signal around the lesion. With SMI, a feeder vessel and internal lesion vascularity was demonstrated.

CEUS also clearly showed the feeder vessel.

One month after RFA, CDI and SMI could not demonstrate any vascularity.

No enhancement was shown with CEUS.



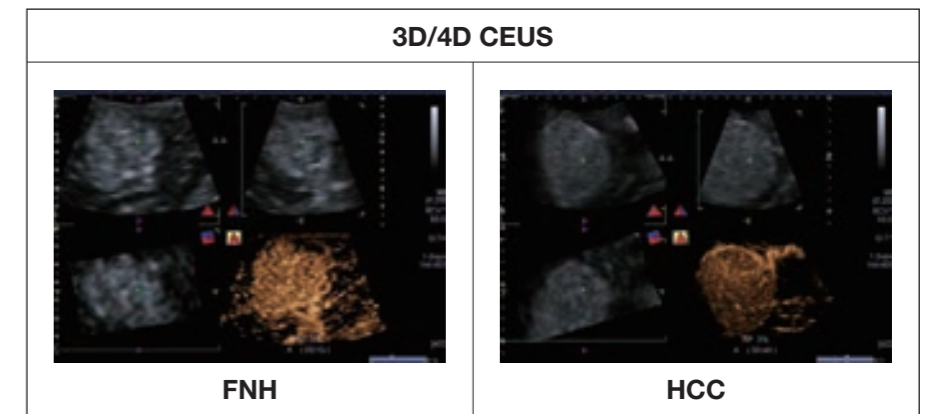
CEUS is the gold standard for evaluating post-RFA results. In this study, results from 47 cases of lesions were compared with CEUS in order to evaluate clinical value of SMI with RFA

evaluation. Each lesion was classified into a category based on SMI results according to the Limberg classification, and the CEUS enhancement pattern. SMI produced consistent results and

correlation with CEUS in 91.5% of the cases (Table 3).

## 4. Support RFA planning and guiding

The aim of RFA treatment, is to occlude the lesion's feeder vessels. Even though CEUS is able to demonstrate blood perfusion and tumor vasculature, the contrast agent has a fast wash-out with malignant tumors, creating a challenge when planning RFA treatment. Furthermore, the micro-bubbles created during RFA ablation will block the visualization of contrast agents. The SMI technology has been seen to be an important tool in RFA planning and guidance.



4D CEUS Images showing feeding vessel in FNH and HCC.

## Case 1. HCC M 41Y

Prior to RFA, CDI demonstrated vascularity peripheral to the lesion with hyperenhancement in the arterial phase. SMI provided additional detailed information by detecting the internal microvasculature perfusion.

After RFA treatment, CDI and SMI both demonstrated minor vascularity around the lesion.

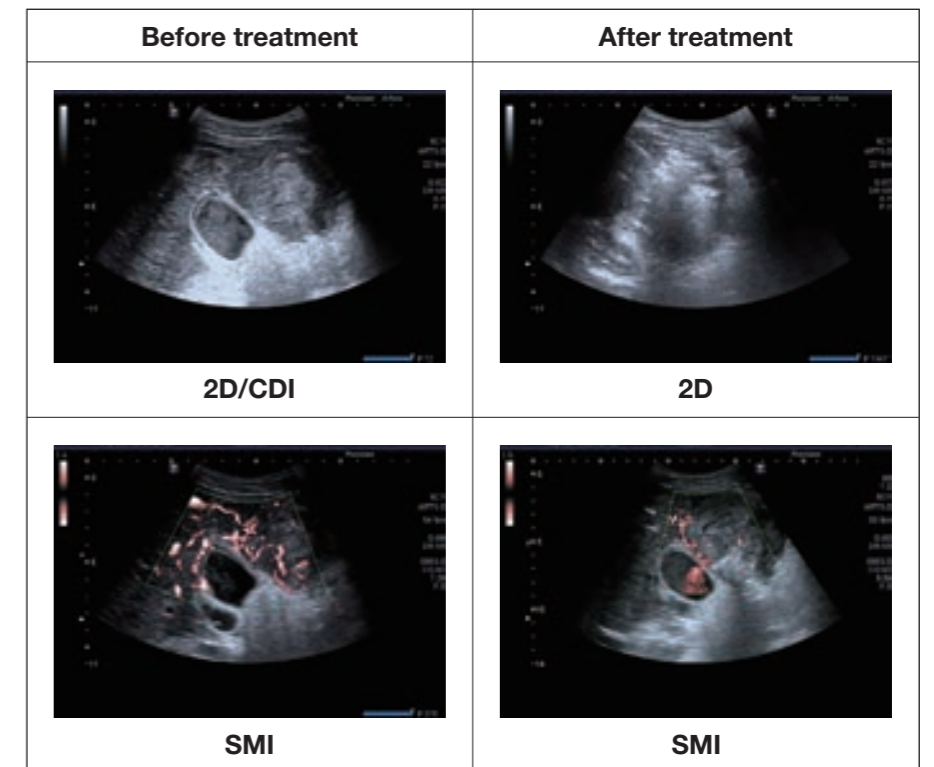


Table 3.

CEUS		SMI			
		I	II	III	IV
	Enhanced	4	5	13	19
	No enhancement	6	0	0	0
<b>Total</b>	<b>N=47</b>	<b>10</b>	<b>5</b>	<b>13</b>	<b>19</b>

There was 100% correlation between SMI and CEUS for level II, III, IV lesions. However at Level I, 4 cases demonstrated enhancement in CEUS but not with SMI. This aberration reflects on the size of the micro-bubbles which are of a similar size to the red blood corpuscles during portal phase. These cells are able to enter the minute capillaries where Doppler technology is limited. It is interesting to note that SMI was seen to demonstrate the same sensitivity as CEUS in the arterial phase.